

# Long-term efficacy follow-up on two cryolipolysis case studies: 6 and 9 years post-treatment

Eric F. Bernstein, MD, MSE

Main Line Center for Laser Surgery, Ardmore, PA, USA

## Summary

Cryolipolysis is a noninvasive esthetic procedure that utilizes controlled cooling to reduce subcutaneous fat. Clinical studies have established its safety, efficacy, and tolerability for fat reduction in a variety of areas including the abdomen, flanks, thighs, submental area, arms, back, and chest. Because of obvious esthetic concerns, long-term unilateral studies leaving an untreated flank, thigh, or arm are not performed, but serve as ideal controls for weight gain or loss or re-distribution of fat for other reasons. This article follows two patients previously documented in a case report to demonstrate their ongoing treatment efficacy at 6 and 9 years after treatment. Clinical photographs of the treated flanks and untreated contralateral controls demonstrate long-term durability in these two subjects.

*Keywords:* cryolipolysis, durability, long-term efficacy, longitudinal study, noninvasive body contouring, nonsurgical fat reduction

## Introduction

Interest in cosmetic procedures continues to grow as patients turn to both surgical and nonsurgical procedures for esthetic improvement. The American Society for Aesthetic Plastic Surgery's cosmetic surgery national data bank statistics reported that in 2015, there were almost 13 million cosmetic procedures performed in the United States and over 13.5 billion dollars spent.<sup>1</sup> Liposuction remained the most popular surgical procedure; meanwhile, interest in nonsurgical alternatives

remained high with 42% of the cosmetic procedures being nonsurgical, surpassing the 5 billion dollar mark.<sup>1</sup>

The demand for noninvasive forms of body contouring has been met by numerous techniques that utilize energy-based modalities such as radiofrequency, ultrasound, laser, and infrared light. The most well-established nonsurgical body contouring procedure is cryolipolysis (CoolSculpting; ZELTIQ Aesthetics, Pleasanton, CA, USA), the controlled application of cooling to noninvasively reduce subcutaneous fat. Cryolipolysis was developed after observations of cold-induced panniculitis, with subsequent atrophy, in both children and adults<sup>2–4</sup> and a case report of popsicle panniculitis<sup>5</sup> led investigators to explore controlled cooling to remove fat. Safety and efficacy of cryolipolysis was first established in porcine models.<sup>6,7</sup> Subsequent human clinical studies demonstrated safety and efficacy in a number of treatment areas including the abdomen, flanks, thighs, and submental areas.<sup>8–15</sup> Clinical studies have also demonstrated safety and effectiveness for the reduction of undesirable fat of the back, arms, and chest.<sup>16–21</sup> The safety of cryolipolysis treatments has also been

Correspondence: Eric F. Bernstein, Main Line Center for Laser Surgery, 32 Parking Plaza, Suite 200, Ardmore, PA 19003, USA.  
E-mail: [dermguy@dermguy.com](mailto:dermguy@dermguy.com)

Accepted for publication May 9, 2016

This is an open access article under the terms of the Creative Commons Attribution-NonCommercial-NoDerivs License, which permits use and distribution in any medium, provided the original work is properly cited, the use is non-commercial and no modifications or adaptations are made.

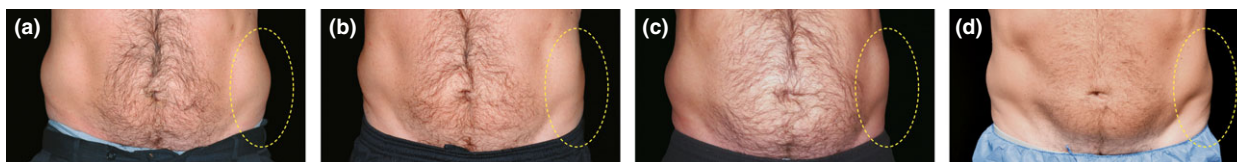
demonstrated in clinical studies where serum lipid levels and liver function tests were performed,<sup>22</sup> as well as peripheral nerve studies,<sup>23</sup> all demonstrating no abnormalities following treatment.

Cryolipolysis received U.S. Food and Drug Administration (FDA) clearance for the fat reduction of the flanks in 2010, abdomen in 2012, thighs in 2014, and the submental area in 2015. Cryolipolysis is a popular nonsurgical body contouring procedure because of its safety, efficacy, tolerability, and durability. In a previously published article, long-term durability of fat reduction was demonstrated in two subjects that received unilateral cryolipolysis flank treatment. The subjects had an untreated contralateral flank to control for fluctuations in weight, and durability of the fat reduction was demonstrated for up to five years following a single treatment.<sup>24</sup> This article follows these two subjects further to evaluate the treatment effect up to 9 years post-treatment.

## Cryolipolysis long-term follow-up

### Case 1

A 44-year-old male presented with unwanted subcutaneous fat in his flanks. At baseline, the patient weighed 205.0 pounds with a BMI of 27.0. The patient opted to have his left flank treated while maintaining an untreated contralateral control. His left flank was treated with two cryolipolysis cycles using a Cooling Intensity Factor (CIF) of 42. Treatment was delivered at commercial parameters maintaining a temperature  $-10^{\circ}\text{C}$  using a 60 min treatment duration. The treatment applicators were positioned anterior to posterior over the flank with approximately 50% overlap and delivered sequentially in one visit. Side effects, such as erythema and numbness, were typical, mild, and resolved without intervention. Clinical photographs documented the treatment and untreated sites at baseline before treatment, 2 months post-treatment, 2 years post-treatment, and 6 years post-treatment



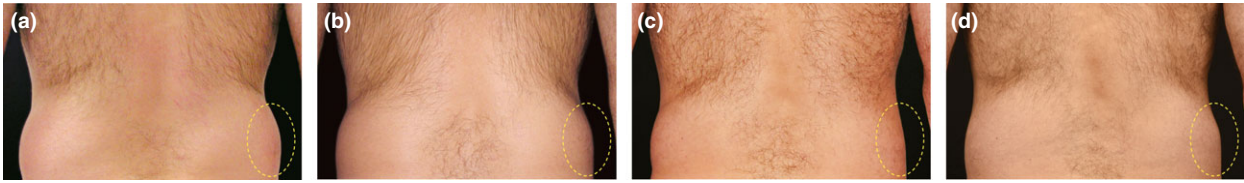
**Figure 1** Pre- and post-treatment images of a now 48-year-old male that received two cryolipolysis treatment cycles to his left flank. Clinical photographs show subcutaneous fat reduction between (a) baseline, (b) 2 months post-treatment, (c) 2 years post-treatment, and (d) 6 years post-treatment. This subject had a weight change of +10.0 lbs. from baseline at 2 years and a weight change of +5.2 lbs. from baseline at 6 years.

(Fig. 1). Weight fluctuations were captured during the subject's follow-up visits, showing the patient had a weight change of +10.0 lbs. (215.0 lbs.) from baseline at 2 years following treatment, and a weight change of +5.2 lbs. (210.2 lbs.) from baseline at 6 years after treatment.

### Case 2

A 45-year-old male presented with excess subcutaneous fat in his flanks. At baseline, he weighed 190.0 pounds with a BMI of 23.7. Despite an active lifestyle, the excess flank fat did not respond to diet and exercise. To evaluate the efficacy of cryolipolysis, the patient chose to have his right flank treated with cryolipolysis while preserving his contralateral flank as an untreated control, but never returned for treatment of the contralateral flank. His right flank was treated with one cryolipolysis cycle using a CIF of 34. Treatment was delivered using parameters commonly used shortly after development of the cryolipolysis procedure with a temperature of  $-5^{\circ}\text{C}$  and a treatment time of 60 min. Treatment effect was evaluated by comparing clinical photographs at baseline, 3 months post-treatment, 5 years post-treatment, and 9 years post-treatment (Fig. 2). The patient had a weight change of  $-10.0$  lbs. (180.0 lbs.) from baseline at 5 years post-treatment and was back to within  $-0.2$  lbs. (189.8 lbs.) from his baseline weight 9 years following treatment.

To quantify treatment efficacy, photographs of the two cases at all time points were evaluated by a panel of three blinded physician reviewers board-certified in either dermatology or plastic surgery. The post-treatment photographs were randomized with pretreatment images and presented to the independent panel. The reviewers were asked to evaluate the flank contours and to identify the pretreatment image. For both patient cases at all three post-treatment time points, the three reviewers correctly identified the baseline images 100% of the time (18 of 18 correct).



**Figure 2** Pre- and post-treatment images of a now 55-year-old male that received a single cryolipolysis treatment to his right flank. Clinical photographs show subcutaneous fat reduction between (a) baseline, (b) 3 months post-treatment, (c) 5 years post-treatment, and (d) 9 years post-treatment. This subject had a weight change of  $-10.0$  lbs. from baseline at 5 years and  $-0.2$  lbs. weight change from baseline at 9 years.

## Discussion

The two patients presented here were treated in the early days of cryolipolysis and present a rare opportunity to investigate long-term efficacy of this treatment, while completely controlling for weight fluctuations. For the subject described in Case 1, the clinical photographs document baseline subcutaneous fat distribution and any pre-existing asymmetry between his flanks (Fig. 1). Despite weight changes over the years, the treated left flank showed a persistent reduction in size and a change in contour. The patient gained 10.0 lbs. at his 2-year follow-up visit and still displayed reduced fat thickness in his left flank. At his 6-year follow-up visit, he appeared leaner at +5.2 lbs. from his baseline weight and photographs still showed a reduction in the treated flank relative to the untreated control.

The patient described in Case 2 was treated using an early version of the cryolipolysis system and thus was treated at a warmer temperature than current commercial cryolipolysis treatments utilize. This subject also had a good treatment response with a reduction in his treated flank as compared to baseline. The patient's treated, right flank appeared to have greater subcutaneous fat thickness than the contralateral side, pretreatment. The patient lost 10.0 lbs. by his 5-year follow-up visit and regained the weight to 189.8 lbs. at 9 years post-treatment. The flank contour in his treated right side remained reduced while his control left flank showed no noticeable change. Having an untreated, control flank allows one to ignore fluctuations in weight when comparing one side to the other.

Photographs of these two cases show that local reductions in flank fat have significant longevity in these subjects and suggest that results from cryolipolysis may be very long-lasting. Existing asymmetries between the treated and untreated contralateral sides are maintained and still visible in clinical photographs at all follow-up time points.

As noninvasive body contouring is still a relatively new procedure, little long-term efficacy data are available. The cases reported here demonstrate 6- and 9-year efficacy in unilateral flank cryolipolysis treatments. These two cases suggest that studies of larger populations of subjects for long-term efficacy of cryolipolysis are warranted. Future longitudinal studies incorporating a large number of subjects could evaluate the extent to which cryolipolysis results are durable over time and would contribute to our understanding of this unique, fat-selective treatment.

## Conclusion

Two patients treated early in the evolution of cryolipolysis are evaluated for long-term durability of their cryolipolysis response. Both male patients had unilateral flank treatments and are unique examples of longitudinal case studies with untreated controls. These cases demonstrate that cryolipolysis reduces subcutaneous fat for at least 6 and 9 years post-treatment in these two subjects. These results suggest that larger longitudinal studies should be carried out to quantify the extent and duration of cryolipolysis results.

## Disclosures

The author is a member of the ZELTIQ Medical Advisory Board.

## References

- 1 American Society for Aesthetic Plastic Surgery (ASAPS) 2015 Cosmetic Surgery National Data Bank Statistics.
- 2 Collins HA, Stahlman M, Scott HW Jr. The occurrence of subcutaneous fat necrosis in an infant following induced hypothermia used as an adjuvant in cardiac surgery. *Ann Surg* 1953; **138**: 880–5.
- 3 Rotman H. Cold panniculitis in children. Adiponecrosis E frigore of Haxthausen. *Arch Dermatol* 1966; **94**: 720–1.

- 4 Solomon LM, Beerman H. Cold panniculitis. *Arch Dermatol* 1963; **88**: 897–900.
- 5 Epstein EH Jr, Oren ME. Popsicle panniculitis. *N Engl J Med* 1970; **82**: 966–7.
- 6 Manstein D, Laubach H, Watanabe K *et al*. Selective cryolipolysis: a novel method of non-invasive fat removal. *Lasers Surg Med* 2008; **40**: 595–604.
- 7 Zelickson B, Egbert BM, Preciado J *et al*. Cryolipolysis for noninvasive fat cell destruction: initial results from a pig model. *Dermatol Surg* 2009; **35**: 1462–70.
- 8 Bernstein EF, Bloom JD, Basilavecchio LD *et al*. Non-invasive fat reduction of the flanks using a new cryolipolysis applicator and overlapping, two-cycle treatments. *Lasers Surg Med* 2014; **46**: 731–5.
- 9 Garibyan L, Sipprell WH 3rd, Jalian HR *et al*. Three-dimensional volumetric quantification of fat loss following cryolipolysis. *Lasers Surg Med* 2014; **46**: 75–80.
- 10 Shek SY, Chan NP, Chan HH. Non-invasive cryolipolysis for body contouring in Chinese – a first commercial experience. *Lasers Surg Med* 2011; **44**: 125–30.
- 11 Brightman L, Geronemus R. Can second treatment enhance clinical results in cryolipolysis? *Cosmet Dermatol* 2011; **24**: 85–8.
- 12 Boey GE, Wasilenchuk JL. Fat reduction in the inner thigh using a prototype cryolipolysis applicator. *Dermatol Surg* 2014; **40**: 1004–9.
- 13 Stevens WG, Bachelor EP. Cryolipolysis conformable surface applicator for non-surgical fat reduction in lateral thighs. *Aesthet Surg J* 2015; **35**: 66–71.
- 14 Zelickson BD, Burns AJ, Kilmer SL. Cryolipolysis for safe and effective inner thigh fat reduction. *Lasers Surg Med* 2015; **47**: 120–7.
- 15 Kilmer SL, Burns AJ, Zelickson BD. Safety and efficacy of cryolipolysis for noninvasive reduction of submental fat. *Lasers Surg Med* 2016; **48**: 3–13.
- 16 Lee SJ, Jang HW, Kim H *et al*. Non-invasive cryolipolysis to reduce subcutaneous fat in the arms. *J Cosmet Laser Ther* 2016; **18**: 126–9.
- 17 Wanitphakdeedecha R, Sathaworawong A, Manuskiatti W. The efficacy of cryolipolysis treatment on arms and inner thighs. *Lasers Med Sci* 2015; **30**: 2165–9.
- 18 Stevens WG, Pietrzak LK, Spring MA. Broad overview of a clinical and commercial experience with coolsculpting. *Aesthet Surg J* 2013; **33**: 835–46.
- 19 Sasaki GH, Abelev N, Tevez-Ortiz A. Noninvasive selective cryolipolysis and reperfusion recovery for localized natural fat reduction and contouring. *Aesthet Surg J* 2014; **34**: 420–31.
- 20 Dierickx CC, Mazer JM, Sand M *et al*. Safety, tolerance, and patient satisfaction with noninvasive cryolipolysis. *Dermatol Surg* 2013; **39**: 1209–16.
- 21 Munavalli GS, Panchaprateep R. Cryolipolysis for targeted fat reduction and improved appearance of the enlarged male breast. *Dermatol Surg* 2015; **41**: 1043–51.
- 22 Klein KB, Zelickson B, Riopelle JG *et al*. Non-invasive cryolipolysis for subcutaneous fat reduction does not affect serum lipid levels or liver function tests. *Lasers Surg Med* 2009; **41**: 785–90.
- 23 Coleman SR, Sachdeva K, Egbert BM *et al*. Clinical efficacy of noninvasive cryolipolysis and its effects on peripheral nerves. *Aesthetic Plast Surg* 2009; **33**: 482–8.
- 24 Bernstein EF. Longitudinal evaluation of cryolipolysis efficacy: two case studies. *J Cosmet Dermatol* 2013; **12**: 149–52.